

Anti-photoaging efficacy and safety evaluation of retinol combined with soy isoflavones

Yu, Yu²; Jia, Kai¹; Ding, Song¹; Yang, Ke¹; **Liu, Chenguang^{2*}**;

¹ Qingdao Youdo Bioengineering Co., Ltd, Qingdao, Shandong, China;

² College of Marine Life Science, Ocean University of China, Qingdao, Shandong, China

*Liu, Chenguang; Room 105, Science Building, Ocean University of China, No.5 Yushan Road, Shinan District, Qingdao, Shandong, China; 13573865801; liucg@ouc.edu.cn

Abstract

Background: Skin photoaging is a multifactorial process mainly influenced by UVA and UVB radiation, UVB directly affects cells and extracellular components, UVA exerts its harmful effects mainly through active oxides. Active oxides destroy lipids and proteins in sebocytes, the extracellular matrix of the skin. It can cause erythema, inflammation, collagen damage, elastic fiber deformation and other phenomena. Photoaging skin manifests as: roughness, sagging and wrinkles. Retinoids can promote the generation of fibroblasts, reduce the degradation of collagen, increase and improve the amount of collagen in the skin, and are widely used in the prevention and treatment of skin photoaging. Retinoids include vitamin A and a range of other metabolites, such as retinol, retinaldehyde, retinyl esters, retinoic acid, and some synthetic derivatives, but retinoids will bring certain adverse reactions, such as dryness, erythema, desquamation, etc. Therefore, how to effectively and safely resist skin photoaging is very important. In this study, topical retinol combined with soy isoflavones was used to observe its efficacy and safety in resisting facial photoaging.

Methods: Select 30 subjects and use cream containing 0.1% retinol + 0.02% soy isoflavones on the face. After a 28-day observation period, the subjects' skin dryness, skin elasticity, dermis thickness and local wrinkle were evaluated, and safety assessment was evaluated through human patch test and consumer questionnaire test.

Results: The skin dryness, skin elasticity, dermal thickness and local wrinkles of the 30 subjects were improved, and there were no adverse reactions in the subjects during the test.

Conclusion: External application of retinol combined with soy isoflavones can improve skin photoaging, which is safe and effective.

Keywords: retinol, isoflavones, skin photoaging

Introduction.

The skin is the body's first line of defense and plays an important role in resisting external aggression, maintaining the internal environment and safeguarding physiological functions. Skin aging is not only affected by natural aging factors, but also directly exposed to the external environment, and is affected by exogenous aging. The strongest, UV-induced aging is called photoaging^[1]. In addition to sagging skin, obvious dryness and desquamation, photoaging skin will also have photoaging-specific manifestations such as skin thickening, hyperkeratosis, hyperpigmentation, and telangiectasia. Histologically photoaged skin is characterized by epidermal atrophy and reduced collagen and elastin^[2-3]. There are many methods for clinical treatment of facial skin photoaging, including chemical peeling, topical preparations, physical therapy, and surgical treatment. Physiotherapy includes laser, radio frequency, etc. Surgical treatment including botulinum toxin injection, hyaluronic acid filling, etc. The above methods can improve the skin quality of patients. However, chemical peeling, physical indicators, and surgical treatment have shortcomings such as a long recovery period and many complications, such as scarring, pigmentation, and skin infections^[4]. Topical skin preparations are a safe and effective means of preventing photoaging and improving symptoms of photoaging.

It has been shown that retinol inhibits UV-induced metalloproteinases and stimulates collagen synthesis in photoaged skin, with a significant improvement in wrinkles observed after 12 weeks of treatment with retinol preparations. Subsequently, topical application of 1% retinol for 7 days was investigated to decrease metalloproteinase activity, accompanied by an increase in fibroblast growth and collagen^[5]. Retinoids include vitamin A and a range of other metabolites, such as retinol, retinaldehyde, retinyl esters, retinoic acid, and some synthetic derivatives. Retinoids are found in keratinocytes in two forms: retinol and retinyl esters. These lipophilic organic compounds are important for epithelial differentiation, immune regulation, vision^[6].

Retinol is an anti-aging topical preparation recognized by the dermatology and cosmetics industry, but it will bring certain adverse reactions. The use of certain compounds can avoid or reduce the adverse reactions caused by the use of retinol to a certain extent. In this experiment, topical retinol combined with soy isoflavones was used to observe its effectiveness and tolerance in anti-facial photoaging.

Materials and Methods.

1.Materials

(1) Select 30 subjects with wrinkles at the corners of the eyes, between the eyebrows and foreheads, aged 35-55 years old. Subjects maintained their daily skin care habits, Subjects who started using sex hormones or oral contraceptives 3 months before the trial could not stop taking the drug during the trial, avoid artificial UV exposure during the test, all subject resources participated in this study and signed informed consent.

(2) Case exclusion criteria: 4 months of internal and external use or internal use of vitamin A acid preparations such as: vitamin A acid moisturizing cream, tazarotene, adapalene, etc, pregnant or breastfeeding women, those with a history of cosmetic allergies or other severe allergies, patients with systemic disease or severe skin disease.

(3) External preparation: lab made, contains 0.1% retinol + 0.2% soy isoflavone cream.

2.Equipments

Dermalab(Dermalab Series SkinLab Combo)

VISIA(VISIA-CR22 , Canfield)

3.Methods

The subjects used the test product on the whole face at home for a total of 28 days, once a night, and kept using their daily skin care products throughout the test period. The test time is before use (D₀) and 28 days after use (D₂₈). During the test, strictly pay attention to sun protection and maintain a good sleep.

3.1. Skin stratum corneum moisture detection

After sitting for 30 minutes in a constant environment (temperature $25 \pm 2^{\circ}\text{C}$, relative humidity $50\% \pm 10\%$), use Dermalab to test the moisture content of the skin, and record the test data. Record the skin moisture value before use and 28 days after use, and calculate the skin moisture improvement rate. The higher the ratio, the better the skin moisture improvement effect.

3.2. Skin elasticity test

Use Dermalab to test skin elasticity and enter the "Elasticity" test interface. Install a double-sided adhesive ring on the surface of the probe in contact with the skin, then attach the probe to the skin test site before removing the adhesive cover. Before placing the probe, the skin surface should be kept clean and dry for the probe to attach. During the measurement, care should be taken to avoid muscle movement, as muscle tension may affect the measurement. Record the skin elasticity value before use and 28 days after use, and calculate the skin elasticity improvement rate. The higher the ratio, the better the skin elasticity improvement effect.

3.3. Skin ultrasound test

Ultrasound of the skin using Dermalab to record the thickness of the test dermis before and 28 days after use. Observation of collagen distribution in epidermis and dermis. Record the thickness of skin dermis before use and 28 days after use, and calculate the improvement rate of skin dermis thickness. The higher the ratio, the better the improvement effect of skin dermis thickness .

3.4. Skin Wrinkle Detection

Take pictures with VISIA to observe skin wrinkles before and 28 days after use.

3.5. Human patch test

Select the appropriate spot test material, put the test substance into the spot tester, and the dosage is about 0.03g solid. The patch tester with the test substance was attached to the inner side of the subject's forearm with non-irritating tape, one side was the control area, the other side was the test area, and it was evenly applied to the skin with the palm of your hand for 24 hours. After removing the test object spot test device, the interval was 30 minutes, and the skin reaction was observed after the indentation disappeared. If the result is negative, observe and record the results at 24h

and 48h respectively of the patch test. When there are more than 2 cases of grade 2 adverse skin reactions among the 30 subjects or any one case of skin adverse reactions of grade 3 or above, it is determined that the test substance has adverse reactions to the human body.

Table1 Skin adverse reactions grading standard

Level of reaction	Rating scale	Skin reaction
-	0	negative reaction
±	1	Suspicious reaction, only faint erythema
+	2	Weak positive reaction (erythema reaction); erythema, infiltrates, edema, and possibly papules
++	3	Strong positive reaction (herpetic reaction); erythema, infiltration, edema, papules, herpes; reverse It should be possible to go beyond the test area
+++	4	Very strong positive reaction (confluent herpes reaction); marked erythema, severe infiltration, edema, Confluent herpes; reaction beyond test area

3.6.Effect test standard

Assessed by the subject after the test. The content includes: According to the self-assessment questions provided, the subjects themselves evaluated the improvement of facial wrinkles, elasticity and gloss, and the results were expressed on a scale of 0-10, with 0 indicating the worst effect and 10 indicating the most improvement. Overall validity: Subjects' satisfaction with the test results, the

evaluation is divided into very satisfied, satisfied, average, dissatisfied. Subject tolerance evaluation: Subjects evaluated possible uncomfortable symptoms such as skin erythema and edema, and the score was divided into 4 grades: 0= poor tolerance, 1= moderate tolerance, 2=tolerance Good sex; 3 = very well tolerated.

3.7. Data processing

SPSS statistical software was used for data analysis, and the statistical method used analysis of variance, and $P < 0.05$ indicated that the difference was statistically significant.

Skin improvement rate after using the product= ((after use data - before use data) / before use data

Results.

1. Skin photoaging improvement

All 30 subjects completed the test as required, using Dermalab to test the improvement rate of skin moisture content and elasticity before use and 28 days after use. Test skin moisture content improvement rate and elasticity improvement rate before and after operation using Dermalab. Dermalab was used to perform skin ultrasound to observe the changes in the dermis of the skin, and VISIA was used to take pictures to observe the changes in wrinkles. After 28 days of use in all subjects, the improvement rate of skin moisture was 33.4%, the improvement rate of elasticity was 11.2%, and the improvement rate of dermal layer thickness was 8.2%, improved to a greater extent ($P < 0.05$). Typical cases are shown in Figure 1 and Figure 2.


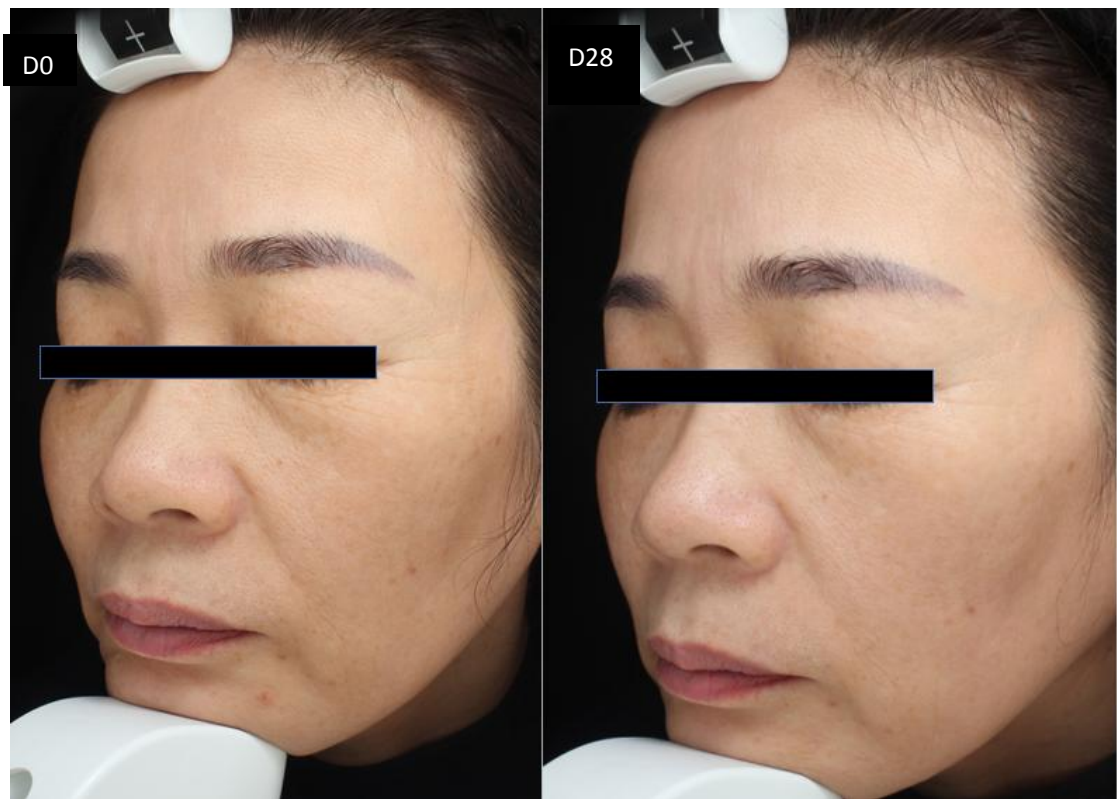


Fig. 1 The changes of collagen content in the dermis of the skin were evaluated by skin ultrasound. The skin ultrasound was detected by Dermalab before the test and after 28 days of using the product. The collagen content in the dermis increased significantly.

(a)



(b)

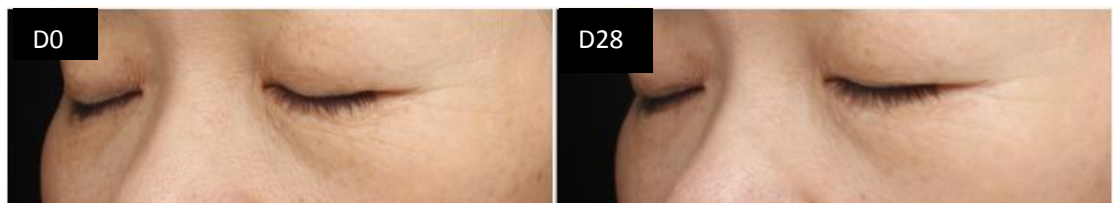


Fig. 2 Skin wrinkle improvement effect (a) Facial images were taken with VISIA before the test and after 28 days of product use. (b) In image (a), the periocular image is magnified.

2. Human patch test

In this study, a total of 30 subjects were collected for skin closed patch test, and the skin reaction of the subjects was observed after removing the patch tester for 30min, 24h, and 48h. The data are in Tables 1, 2, and 3.

Table 1 Skin reaction after 30 minutes of removing spot tester

Sample serial number	0	1	2	3	4
blank	30	0	0	0	0
test substance	30	0	0	0	0

Table 2 Skin reaction after 24h of removing spot tester

Sample serial number	0	1	2	3	4
blank	30	0	0	0	0
test substance	30	0	0	0	0

Table3 Skin reaction after 48h of removing spot tester

Sample serial number	0	1	2	3	4
blank	30	0	0	0	0
test substance	30	0	0	0	0

3. Subject self-assessment

According to the self-assessment questions provided, the subjects themselves assessed the degree of improvement in facial wrinkles, elasticity, and gloss. The facial wrinkle evaluation score was 7.9 points, the elasticity score was 7 points, and the glossiness score was 7.8 points. Overall validity: The subjects' overall satisfaction with the test results reached 96.7%. Subjects assessed tolerance with a score of 3.

Discussion.

The cream containing 0.1% retinol + 0.2% soy isoflavones in this article can improve dry skin, improve skin elasticity, reduce skin wrinkles, and improve skin dermis thickness.

Skin photoaging manifests as: roughness, laxity, and wrinkles. Studies have shown that retinol can increase the content of mucopolysaccharides in the epidermis of aging skin, mucopolysaccharides keep the skin more hydrated at the molecular level, thereby making the skin more moisturizing and improving skin fine lines^[7]. In this test, the use of 0.1% retinol + 0.2% soy isoflavone cream can improve the moisture content in the skin, and it is inferred that the improvement of skin fine lines and the increase of skin elasticity and moisture are also related.

Ultraviolet rays are an important cause of skin photoaging, UV light induces the release of free radicals in the skin. At the molecular level, UV light activates the cell surface receptors of keratinocytes and fibroblasts in the skin, initiating signal transduction reactions that lead to the breakdown of collagen in the extracellular matrix and the synthesis of new collagen. UV-induced activation of multiple transcription factors in skin cells, including factor-activated protein 1 (AP-1), AP-1-induced matrix upregulation of metalloproteinases degrades connective tissues, such as collagen and elastin, and indirectly inhibits collagen synthesis^[8-10]. Clinically, skin atrophy, decreased elasticity, wrinkles, etc. Studies have shown that retinol anti-aging effects include inhibition of the effects of UV radiation on matrix metalloproteinases and promotion of collagen synthesis in photoaging skin . Experiments have shown that retinol can stimulate the growth of keratinocytes and fibroblasts in natural aging and photoaging skin in vitro organ culture and monolayer cell culture, increase collagen type I and fibronectin synthesis. Researchers have shown that retinol can play an anti-photoaging effect on skin by increasing elastin synthesis and alignment^[11]. When the skin undergoes physiological aging, or is damaged by ultraviolet rays and trauma, retinol can correct or prevent the abnormality of the biochemical composition and morphological structure of the dermal connective tissue caused by harmful factors, stimulate the synthesis of skin extramatrix protein,

and accelerate the formation of new cells in the upper dermis. The connective tissue band increases the tension strength of the wound site. Increased dermal thickness may be a result of the formation of new tissue bands in the upper dermis. Therefore, using 0.1% retinol + 0.2% soy isoflavone cream in this test, it can be observed that the skin elasticity of the subjects increases, the thickness of the dermis layer increases, the content of collagen in the dermis layer increases, and the skin wrinkles decrease within 28 days.

Simple retinol cream often causes adverse skin reactions. Some literatures show that the main cause of this adverse reaction is the EGFR protein on the skin surface. When retinol is applied externally to the skin, skin keratinocytes will activate skin epidermal growth factor. Epidermal growth factor can activate EGFR, an intermediate called retinol that causes hyperplasia of skin epidermal cells. Overactive EGFR leads to excessive proliferation of basal epidermal cells, and adverse reactions such as dryness and desquamation occur. Patented technology uses the combination of soy products and apple extract as a natural EGFR inhibitor^[12]. Some literatures indicate that genistein is a natural protein tyrosine kinase inhibitor in addition to its estrogenic activity. Studies have confirmed that genistein can inhibit the EGFR pathway, and soy isoflavones are rich in genistein^[13]. The creams used in this study reduced the skin irritation response to retinol while ensuring the anti-photoaging effect of retinol through the use of retinol and soy isoflavones.

Conclusion.

The results of this study confirm that the retinol-soy isoflavone cream used in this test can effectively improve the symptoms of photoaging, including improving skin moisture, skin elasticity, increasing dermal thickness and collagen content, improving fine lines, and long-term use, no adverse reactions occurred. Suitable as a daily anti-photoaging treatment.

Acknowledgments.

This work was supported by the R&D team of Qingdao Youdo Bioengineering Co., Ltd.

Conflict of Interest Statement.

NONE.

References.

- [1] He Qiu Xia, Gao Jian Li, et al (2022) Dermatoscopic characteristics of photoaged skin and endogenous aged skin. *Dermatology and Venereology* 44:157–160.
- [2] Stern R S (2004) Clinical practice Treatment of photoaging. *New England Journal of Medicine* 350: 1526–1534.
- [3] Sachs D L, Varani J, Chubb H, et al (2019) Atrophic and hypertrophic photoaging: clinical, histologic, and molecular features of 2 distinct phenotypes of photoaged skin. *Journal of the American of Dermatology* 81: 480–488.
- [4] Jiang Hong Ling (2022) Comparative analysis of the efficacy of intense pulsed light and CO₂ fractional laser in the treatment of facial skin photoaging. *China Medical Cosmetology* 102:25-28.
- [5] Farris P K, Rendon M I (2010) The mechanism of action of the topical retinoids for the treatment of nonmalignant photodamage. *Cosmet Dermatol* 23:108-109.
- [6] Sorg O, Saurat J-H (2014) Topical retinoids in skin aging: a focused update with reference to sun-induced epidermal vitamin A deficiency. *Dermatology* 228:314-325.
- [7] Kim JE, Kim B, Kim H, et al (2010) Retinyl retinoate induces hyaluronan production and less irritation than other retinoids. *J Dermatol* 37:448-454.
- [8] Scharrfetter-Kochanek K , Wlaschek M, Briviba K, et al (2010) Singlet oxygen induces collagenase expression in human skin fibroblasts. *FEBS Lett* 331:304-306.
- [9] Dong K K, Damaghi N , Picart S D, et al (2008). UV-induced DNA damage initiates release of MMP-1 in human skin. *Experimental Dermatology* 17:1037-1044.
- [10] Rasche C, Elsner P (2010) Skin aging: a brief summary of characteristic changes. *Textbook of Aging Skin*. Germany : Springer 2010:55-65.
- [11] Rossetti D, Kielmanowicz MG, Vigodman S, et al (2011) A novel anti-ageing mechanism for retinol: induction of dermal elastin synthesis and elastin fibre formation. *Int J Cosmet Sci* 33:62-69.
- [12] Wang Xi, Li Li, et al (2016) Multivitamin A Clinical observation on anti-wrinkle efficacy and safety of cream. *Clin Dermatol* 45:63-66.

[13] Dai Hong Liang, JiaGui Zhi, et al (2015) Anti - proliferative Effects of Genistein on Human Hepatoma SMMC7721 Cells Proliferation via Inhibiting EGFR/ERK Pathway. Liaoning Medical University 36:1-3.